

Boy or Girl? Mother Determines!

The Mother Determines the Baby's Gender, The Father Approves!

N.B.

The Arabic version of this article is the reference, read it via one of the following links:

المرأة تقرّر جنس وليدها، والرجل يدعى!

The Mother Determines the Gender of her Baby, The Father Approves!



Introduction

*I propose the existence of two distinct types of oocytes: **Female Oocytes (FOs)** and **Male Oocytes (MOs)**. FOs exclusively produce female embryos when fertilized by an X sperm, while MOs exclusively produce male embryos when fertilized by a Y sperm. Incompatible fertilization (e.g., an FO with a Y sperm or an MO with an X sperm) results in the termination of embryonic development (Figure 2).*

Incompatible pairings result in developmental arrest (i.e., FO is fertilized by the Y sperm or MO is fertilized by the X sperm, the process of creation is eventually aborted (Figure 1)).

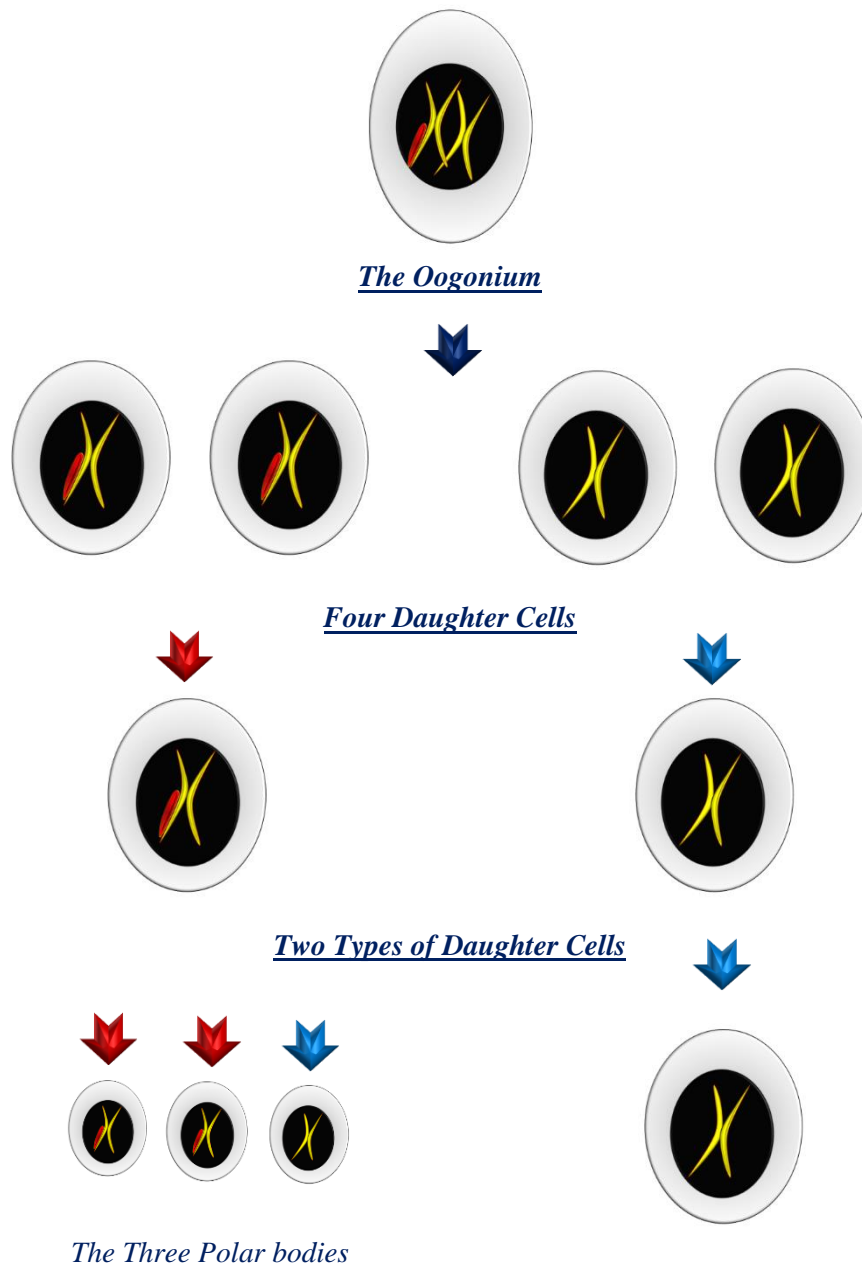
For further details, see the linked video: 

The Oocytogenesis Process

*Oogonia, residing in the ovaries, serve as the origin of both oocyte types. An oogonium is a stem cell containing 46 chromosomes, including two sex chromosomes (XX). These XX chromosomes are not identical; one carries a segment termed "**Adam's Rib**" (highlighted in red in Figure 1), which increases its molecular weight. During meiosis, the XX* pair segregates: the X* chromosome (with Adam's Rib, * denoting Adam's Rib) develops into the **Female Oocyte (FO)**, while the unmarked X chromosome forms the **Male Oocyte (MO)**.*

Note: A single oogonium yields four daughter cells, but only one matures into an oocyte (FO or MO); the remaining three form polar bodies (Figure 1).

[For Further details about the Oocytogenesis, See the linked video:](#) 



The First Option:
The oocyte might contain non-sexual X chromosome; this is the male oocyte (MO)



The second option:

The oocyte contains the female sex X chromosome; and this is the female oocyte (FO)(* denoting Adam's Rib)*

Figure (1)
The Ocytogenesis

After the cell duplicates its chromosomal material, it distributes it into four daughter cells, with every two of them being genetically identical. As a result, there are two types of daughter cells: one containing the female sex chromosome (X) and the other containing the non-sexual chromosome (X).*

Afterward, the law of randomness selects one out of these four daughter cells to become the oocyte, while the remaining three cells become polar bodies.

Here, we face two possibilities regarding the selected oocyte: either it contains the female sex X chromosome, making it a female oocyte, or it contains the non-sex X chromosome, resulting in a male oocyte.*

(* denoting Adam's Rib)

Key Features of Female and Male Oocytes

- **Female Oocyte (FO):** Contains the X* chromosome (with Adam's Rib). This chromosome is the precursor of the **Barr Body**, a structure found in female somatic cells. FOs can only be fertilized by X spermatozoa to form female embryos (Figure 2).
- **Male Oocyte (MO):** Contains a standard X chromosome (lacking Adam's Rib). MOs can only be fertilized by Y spermatozoa to form male embryos. Incompatible fertilization (e.g., MO + X spermatozoon) results in developmental arrest (Figure 2).

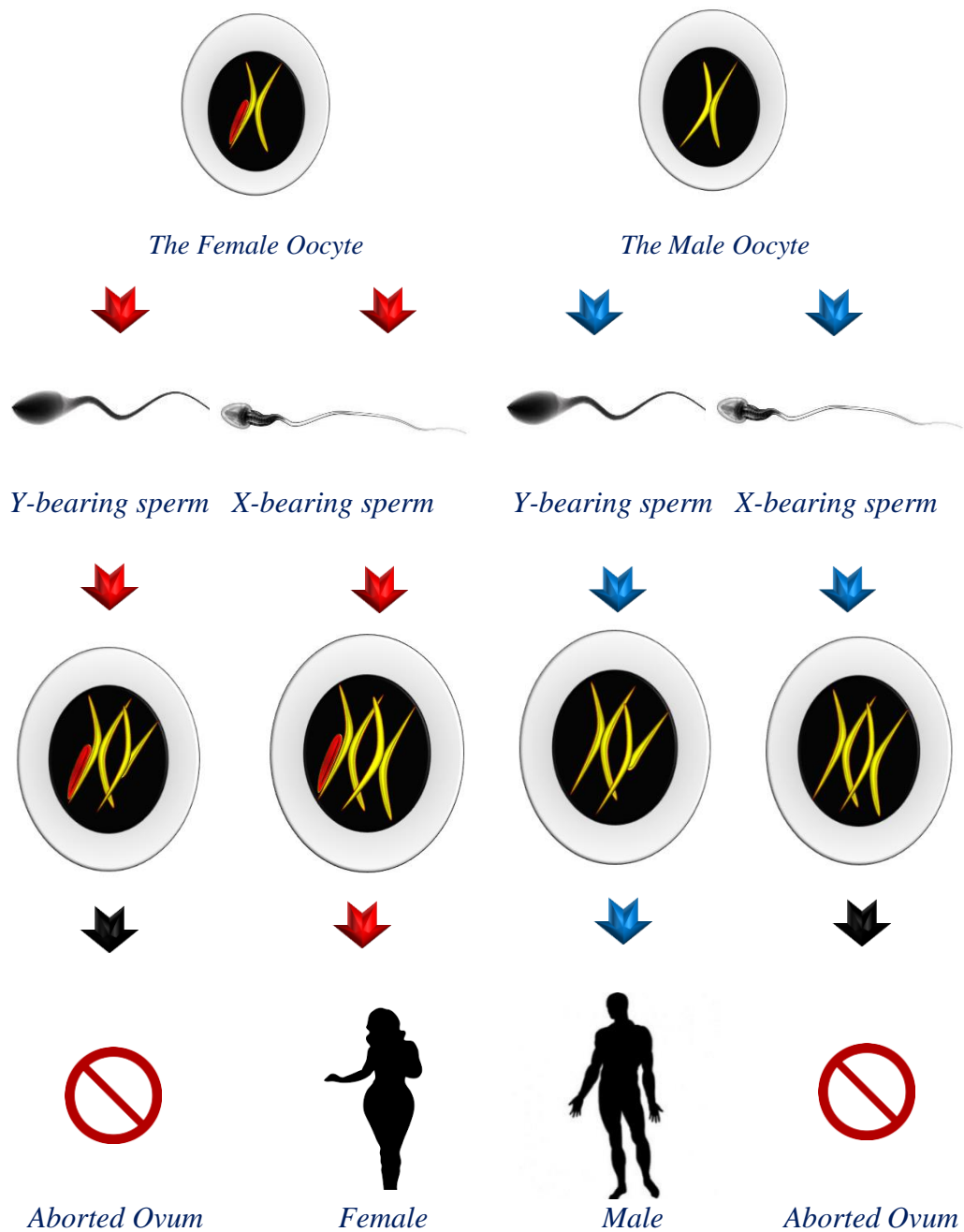


Figure (2)

*The Female Oocyte can only give rise to a female embryo.
If it is fertilized by a compatible sperm cell (e.g., an X-bearing sperm), the creation process proceeds successfully.*

(FO + X spermatozoon = Female embryo)

However, if it is fertilized by an incompatible sperm cell (e.g., a Y-bearing sperm), the creation process is ultimately aborted.

(FO + Y spermatozoon = Aborted Ovum)

The Male Oocyte can only give rise to a male embryo.

*If it is fertilized by a compatible sperm cell (e.g., a **Y-bearing sperm**), the creation process proceeds successfully.
(**MO + Y spermatozoon = Male embryo**)*
*However, if it is fertilized by an incompatible sperm cell (e.g., an X-bearing sperm),
the creation process is ultimately aborted.
(**MO + X spermatozoon = Aborted Ovum**)*

Discussion

Everyone agrees on the absence of a Barr body in the natural male. It is therefore logical to conclude that the Barr body—or any potential precursor to it—is absent in the X sperm and certainly in the Y sperm. Thus, I can assert that the Barr body in females does not originate from the X sperm but rather from the X oocyte. This means that a natural woman's reserve of X oocyte includes those capable of producing a Barr body... This is the first point.

Secondly, let us focus on the male. Since there is no trace of a Barr body in his somatic cells or his sperm, I can conclude that the oocyte from which this male originated was also devoid of a Barr body and its precursor. Consequently, women possess X oocyte that are both free of the Barr body and its precursor.

Combining the first and second points, we find that women have two types of X oocyte: one type is the X oocyte lacking a Barr body or any precursor to it, as evidenced by its absence in natural males. The other type of X oocyte is what produces the Barr body, as seen in natural females. This can only be logically explained by assuming that the X chromosome in the first type differs from the X chromosome in the second type.

From this, the first type of oocytes is considered masculinizing (male-determining), and the second type is feminizing (female-determining). The former cannot produce a female, as there is no natural female without a Barr body. The latter cannot produce a male, as there is no natural male possessing a Barr body.

The division of oocytes into masculinizing and feminizing types necessarily entails differences in the function and possibly the structure of the X chromosome between the two types. It remains for us to determine the nature and origin of this difference. Through inductive analysis, relying heavily on my hypothesis regarding the origin of the Barr body, I conclude

that the X chromosome in the feminizing egg has a greater molecular weight (or size) compared to its counterpart in the masculinizing egg."

This has also compelled me to re-examine Lyon's hypothesis itself regarding the Barr body. I can no longer accept the notion that the Barr body is an inactive X chromosome. In reality—and according to my personal view—the entirety of the functional role lies with the Barr body, while the other X chromosome in the female's XX chromosomal pair has nothing more than a supportive role.

The Barr Body, observed in female somatic cells, originates from the X chromosome in FOs. Its absence in male cells (XY) implies that spermatozoa (X or Y) cannot contribute this structure. Thus, the X* chromosome must derive solely from the oocyte. This supports the classification of oocytes into FO (X*) and MO (X).*

For further details on the Barr Body, click on the following link:

[The Barr Body, the Mystery of its origin and Function](#)



Intracytoplasmic Sperm Injection (ICSI)

*ICSI data reveal that 92% of injected oocytes are fertilized, yet only ~50% develop into viable embryos. Conventional explanations attribute this to sperm chromosomal abnormalities. However, my hypothesis posits that **incompatibility between oocyte type (FO/MO) and sperm (X/Y)** is the true cause. For instance, injecting an X sperm into an MO (destined for a Y sperm) leads to non-viable zygotes with chromosomal disruptions.*

Finally, after all of this, do I not have the right to ask: Who is fundamentally responsible for determining the child's sex—the mother or the father?

Conclusion

The mother's oocyte type (FO or MO) dictates the embryo's sex, while the father's sperm merely provides complementary compatibility. This model challenges traditional views but aligns with observed ICSI outcomes and the role of the Barr Body.


- *FO + X spermatozoon = Female embryo.*







- *MO + Y spermatozoon = Male embryo.*
- *Incompatible pairings result in developmental arrest.*




.....


In other contexts, you can also read the following articles:


-  [*The Spinal Reflex, New Hypothesis of Physiology*](#)
-  [*The Hyperreflexia, Innovated Pathophysiology*](#)
-  [*The Spinal Shock*](#)
-  [*The Spinal Injury, the Pathophysiology of the Spinal Shock, the Pathophysiology of the Hyperreflexia*](#)
-  [*Upper Motor Neuron Lesions, the Pathophysiology of the Symptomatology*](#)
-  [*The Hyperreflexia \(1\), the Pathophysiology of Hyperactivity*](#)
-  [*The Hyperreflexia \(2\), the Pathophysiology of Bilateral Responses*](#)
-  [*The Hyperreflexia \(3\), the Pathophysiology of Extended Hyperreflex*](#)
-  [*The Hyperreflexia \(4\), the Pathophysiology of Multi-Response Hyperreflex*](#)
-  [*The Clonus, 1st Hypothesis of Pathophysiology*](#)
-  [*The Clonus, 2nd Hypothesis of Pathophysiology*](#)
-  [*The Clonus, Two Hypotheses of Pathophysiology*](#)
-  [*The Nerve Transmission through Neural Fiber, Personal View vs. International View*](#)
-  [*The Nerve Transmission through Neural Fiber \(1\), The Action Pressure Waves*](#)
-  [*The Nerve Transmission through Neural Fiber \(2\), The Action Potentials*](#)
-  [*The Nerve Transmission through Neural Fiber \(3\), The Action Electrical Currents*](#)
-  [*The Function of Standard Action Potentials & Currents*](#)
-  [*The Three Phases of Nerve transmission*](#)


-  [*Neural Conduction in the Synapse \(Innovated\)*](#)







-  [*Nodes of Ranvier, the Equalizers*](#)
-  [*Nodes of Ranvier, the Functions*](#)
-  [*Nodes of Ranvier, First Function*](#)
-  [*Nodes of Ranvier, Second Function*](#)
-  [*Nodes of Ranvier, Third Function*](#)
-  [*Node of Ranvier, The Anatomy*](#)




-  [*The Wallerian Degeneration*](#)
-  [*The Neural Regeneration*](#)
-  [*The Wallerian Degeneration Attacks Motor Axons, While Avoids Sensory Axons*](#)





-  [*The Sensory Receptors*](#)










-  [*Nerve Conduction Study, Wrong Hypothesis is the Origin of the Misinterpretation \(Innovated\)*](#)


-  [*Piriformis Muscle Injection _ Personal Approach*](#)



-  [*The Philosophy of Pain, Pain Comes First! \(Innovated\)*](#)
-  [*The Philosophy of the Form \(Innovated\)*](#)
-  [*Pronator Teres Syndrome, Struthers-Like Ligament \(Innovated\)*](#)
-  [*Ulnar Nerve, Congenital Bilateral Dislocation*](#)
-  [*Posterior Interosseous Nerve Syndrome*](#)
-  [*The Multiple Sclerosis: The Causative Relationship Between The Galvanic Current & Multiple Sclerosis?*](#)



-  [*Cauda Equina Injury, New Surgical Approach*](#)
-  [*Carpal Tunnel Syndrome Complicated by Complete Rupture of Median Nerve*](#)
-  [*Biceps Femoris' Long Head Syndrome \(BFLHS\)*](#)



-  [*Barr Body, The Whole Story \(Innovated\)*](#)
-  [*Adam's Rib and Adam's Apple, Two Faces of one Sin*](#)
-  [*Adam's Rib, could be the Original Sin?*](#)
-  [*Barr Body, the Second Look*](#)




-  [*Who Decides the Sex of Coming Baby?*](#)
-  [*Boy or Girl, Mother Decides!*](#)
-  [*Oocytogenesis*](#)
-  [*Spermatogenesis*](#)
-  [*This Woman Can Only Give Birth to Female Children*](#)
-  [*This Woman Can Only Give Birth to Male Children*](#)
-  [*This Woman Can Give Birth to Female Children More Than to Male Children*](#)
-  [*This Woman Can Give Birth to Male Children More Than to Female Children*](#)
-  [*This Woman Can Equally Give Birth to Male Children & to Female Children*](#)









-  [*Eve Saved Human Identity, Adam Ensured Human Adaptation*](#)

-  [*Coronavirus \(Covid-19\): After Humiliation, Is Targeting Our Genes*](#)
-  [*Coronavirus \(Covid-19\): After Humiliation, Is Targeting Our Genes*](#)

-  [*The Black Hole is a \(the\) Falling Star?*](#)
-  [*Mitosis in Animal Cell*](#)
-  [*Meiosis*](#)

-  [*Universe Creation, Hypothesis of Continuous Cosmic Nebula*](#)
-  [*Circulating Sweepers*](#)

-  [*Pneumatic Petrous, Bilateral Temporal Hyperpneumatization*](#)
-  [*Congenital Bilateral Thenar Hypoplasia*](#)
-  [*Ulnar Dimelia, Mirror hand Deformity*](#)

-  [*Surgical Restoration of a Smile by Grafting a Segment of the Gracilis Muscle to the Face*](#)
-  [*Mandible Reconstruction Using Free Fibula Flap*](#)
-  [*Presacral Schwannoma*](#)
-  [*Giant Liver Hemangioma Liver Hemangioma: Urgent Surgery of Due to Intra-Tumor Bleeding*](#)
-  [*Free Para Scapular Flap \(FPSF\) for Skin Reconstruction*](#)
-  [*Claw Hand Deformity \(Brand Operation\)*](#)
-  [*Algodystrophy Syndrome Complicated by Constricting Ring at the Proximal Border of the Edema*](#)
-  [*Non- Traumatic Non- Embolic Acute Thrombosis of Radial Artery \(Buerger's Disease\)*](#)
-  [*Isolated Axillary Tuberculosis Lymphadenitis*](#)
-  [*The Iliopsoas Tendonitis... The Snapping Hip*](#)

[To read the article in Arabic, click on](#) → 



The New Frankenstein Monster



The Lone Wolf



The Delirium of Night and Day



The Delirium of the Economy

27/10/2019